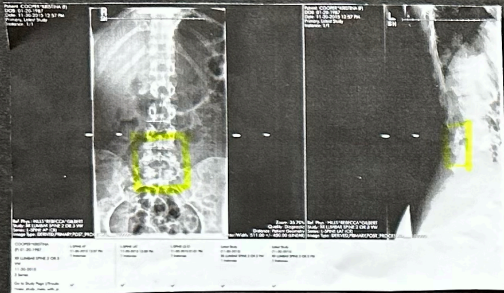
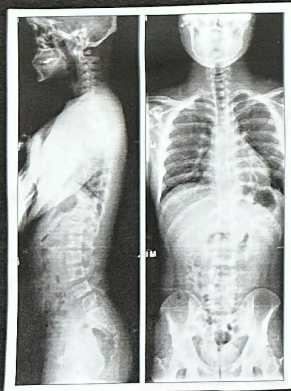

ANKYLOSING SPONDYLITIS

Comparisons



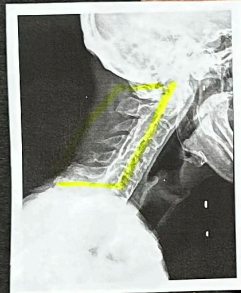
Fused Lumbar Spine
2 & 3.



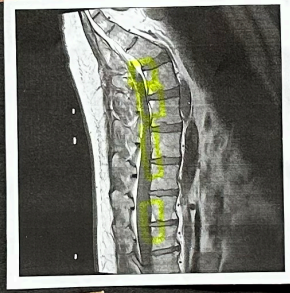
Normal Spine Images

Multiple Thoracolumbar Spondylolysis with Spondylolisthesis at L4 on L5. Scientific Figure on ResearchGate. Available from: https://www.researchgate.net/figure/Normal-standing-spine-X-rays-showing-normal-sagittal-and-coronal-balance_fig2_2811564020 [accessed 25 Jul 2024].

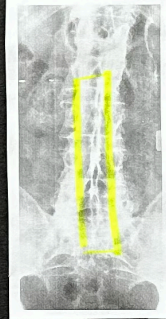
Skeletal Areas Affected



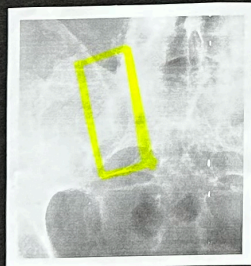
Cervical



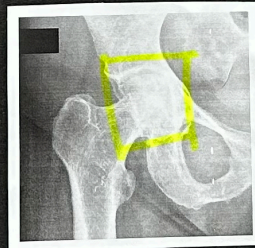Thoracic



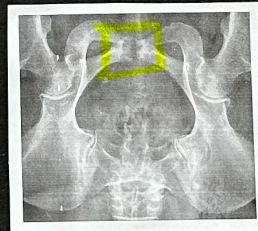
Lumbar



Sacroiliac
Joint



Hip
Joint



Pubic
Symphysis

Suspected & Confirmed

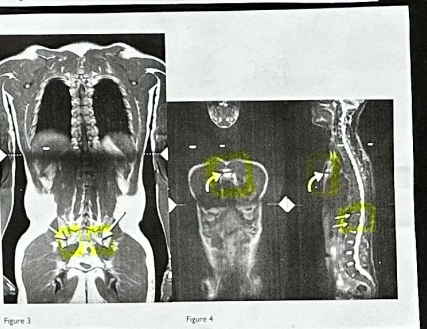
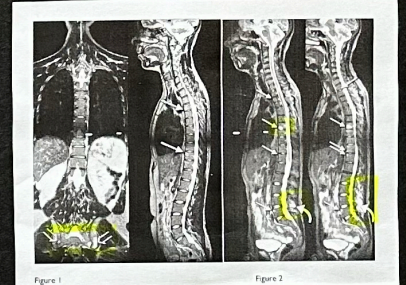


Fig 1: Suspected. Inflammation. SI joints

Fig 2: Confirmed. Inflammation & lesions in Spinous Process.

Fig 3: Confirmed. Inflammation in Pubic.

Fig 4: Confirmed. Inflammation & Lesions in anterior chest & lower thoracic.