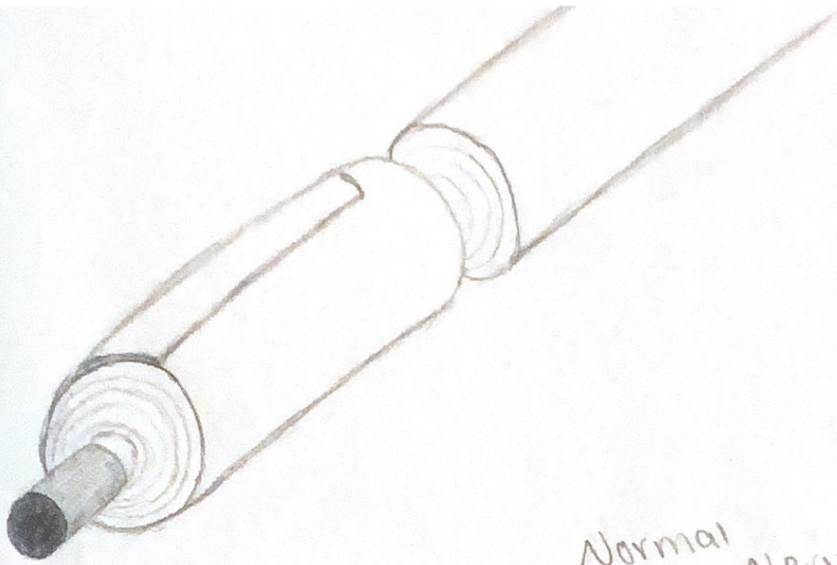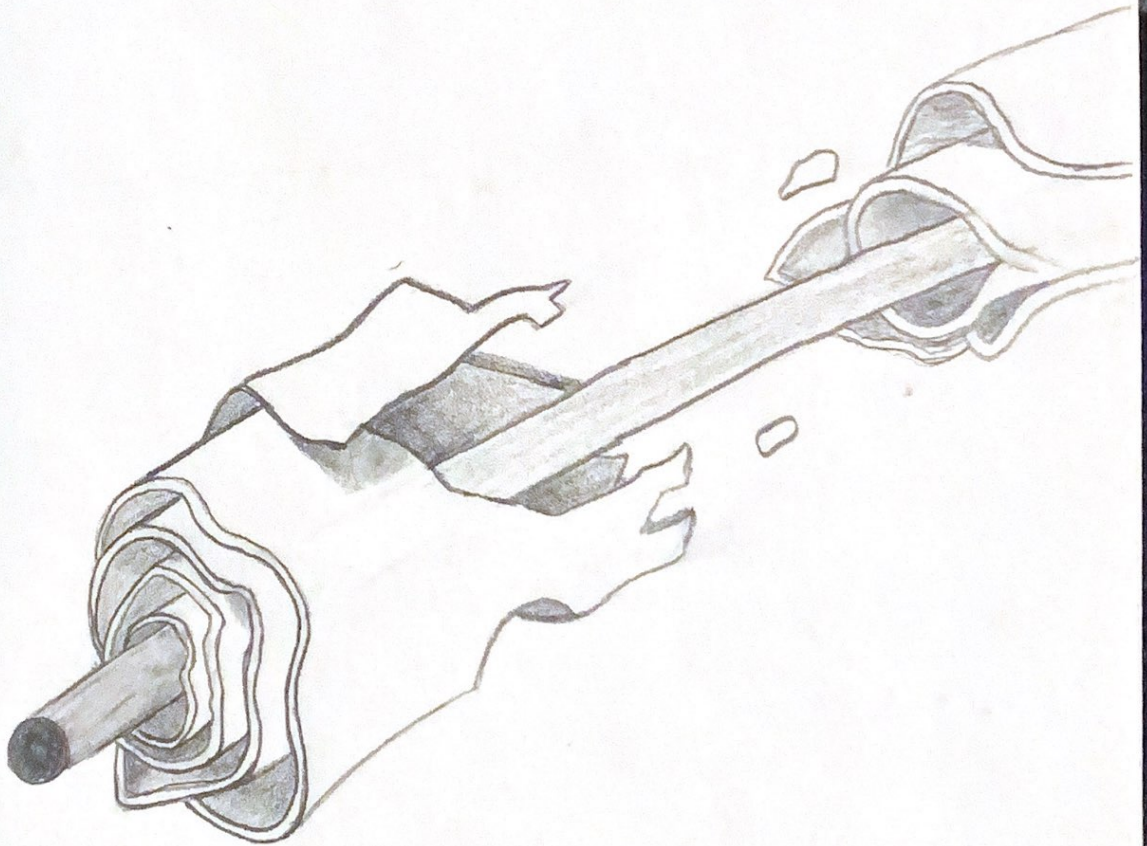


Normal
Nerve



Nerve Affected
by MS