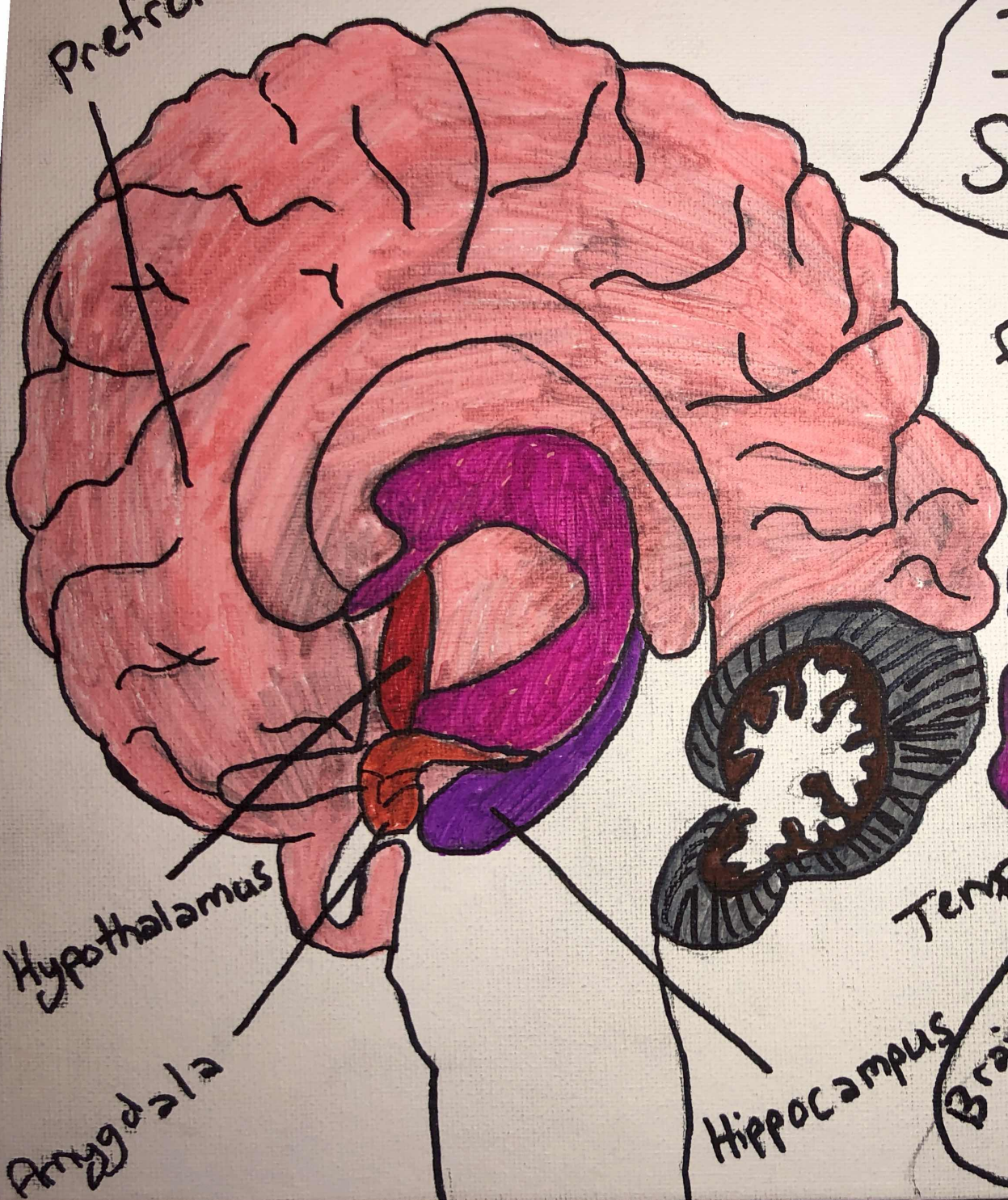


Prefrontal Cortex

Internal Brain Structures Affected



Hypothalamus

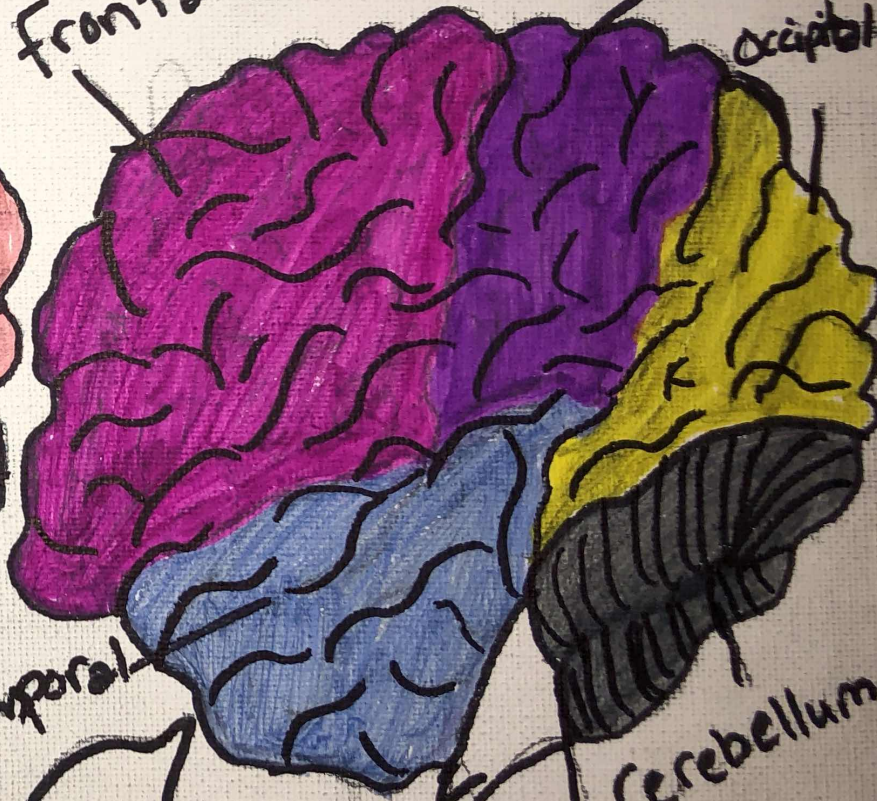
Amygdala



Hippocampus

Frontal

Parietal
Occipital



Temporal

Brain lobes

pons

Cerebellum

medulla
oblongata